



Research Synthesis of Recommended Acetabular Cup Orientations for Total Hip Arthroplasty[☆]

Claire L. Harrison, BEng^a, Avril I. Thomson, PhD^b, Steven Cutts, FRCS^c, Philip J. Rowe, PhD^a, Philip E. Riches, PhD^a

^a Department of Biomedical Engineering, University of Strathclyde, Glasgow, UK

^b Department of Design Manufacture and Engineering Management, University of Strathclyde, Glasgow, UK

^c James Paget University Hospital, Great Yarmouth, UK

ARTICLE INFO

Article history:

Received 26 March 2013

Accepted 15 June 2013

Keywords:

acetabular cup
correct orientation
malpositioning
total hip arthroplasty

ABSTRACT

Total hip arthroplasty (THA) is regarded as one of the most successful surgical procedures of modern times yet continues to be associated with a small but significant complication rate. Many early failures may be associated with poor component positioning with, in particular, acetabular component orientation dependent on the subjective judgement of the surgeon. In this paper, we compare the manufacturers' instructions for acetabular cup orientation with the literature-based recommended safety zones and surgical technique, by transforming them onto a single, clinically-relevant framework in which the different reference systems, safety guidelines and current instrumentation surgical techniques can be evaluated. The observed limited consensus between results reflects ongoing uncertainty regarding the optimum acetabular component positioning. As malpositioning of the acetabular cup increases the risk of revision surgery, any ambiguity over the correct position can have a causal effect. Our analysis highlights the need for a surgical reference system which can be used to describe the position of the acetabular cup intra-operatively.

© 2014 The Authors. Published by Elsevier Inc. All rights reserved.

Success in total hip arthroplasty (THA) is critically dependent on correct acetabular positioning [1]. When the acetabular component is malpositioned, there is an increased risk of impingement, dislocation, pelvic osteolysis and wear and early revision [2–10]. As the annual number of THA procedures increases, the economic burden of revision surgery will increase with it [11].

Errors in component positioning may be the result of poor technique [12]: whilst some surgeons now use computer navigation most continue to use mechanical guides. Navigation systems are considered to extend operating times, are expensive and are associated with a significant learning curve [13]. In the operating theatre environment, surgeons use the vertical and the operating table itself as a reference frame for mechanical guides rather than the patient therefore accurate use of mechanical guides is dependent on the surgeon correctly aligning the guide with this reference. However this technique is based on the assumption that the transverse axis of the pelvis is perfectly perpendicular to the table although, in reality, this is rarely the case [14]. Preoperatively,

optimum orientation is considered by the surgeon based on measurements taken from radiographs however this can be difficult to replicate during surgery.

There is limited consensus in the literature as to what constitutes the optimum orientation of the acetabular component [15]. Differences in reference systems, surgical techniques and measurement systems make objective comparisons of published studies difficult.

Orientations of inclination and anteversion are currently defined in 3 different measurement systems: the radiographic, anatomical and operative orientations; with conversion equations [16] allowing comparison between different manufacturers and literature guidelines. Lewinnick's [3] definition of a 40° lateral opening angle and 15° anteversion with a safety zone of $\pm 10^\circ$ appears to be the most widely accepted as the desired orientation for the acetabular cup and adherence to these guidelines has been shown to reduce the chance of dislocation [3]. In comparison, McCollum and Gray [17] suggested a position of $40^\circ \pm 10^\circ$ abduction and $30^\circ \pm 10^\circ$ flexion to prevent impingement and dislocation. Harris [18] recommends a position of 30° abduction and 20° anteversion; however, the Harris angles are referenced using a mechanical guide and the trunk of the patient. Pedersen [19] used a CAD model to show that a position of less than 40° tilt and less than 10° anteversion would achieve the optimal range of motion. Yoon et al [20] conducted a study comparing some of the current recommendations from literature and converted these into a global system however there is no comparison of manufacturers' instructions and how this impacts current surgical technique.

[☆] This is an open-access article distributed under the terms of the Creative Commons Attribution License, which permits unrestricted use, distribution, and reproduction in any medium, provided the original author and source are credited.

The Conflict of Interest statement associated with this article can be found at <http://dx.doi.org/10.1016/j.arth.2013.06.026>.

Reprint requests: Claire L. Harrison, Department of Biomedical Engineering, University of Strathclyde, Wolfson Centre, 106 Rottenrow, Glasgow, G4 0NW, UK.

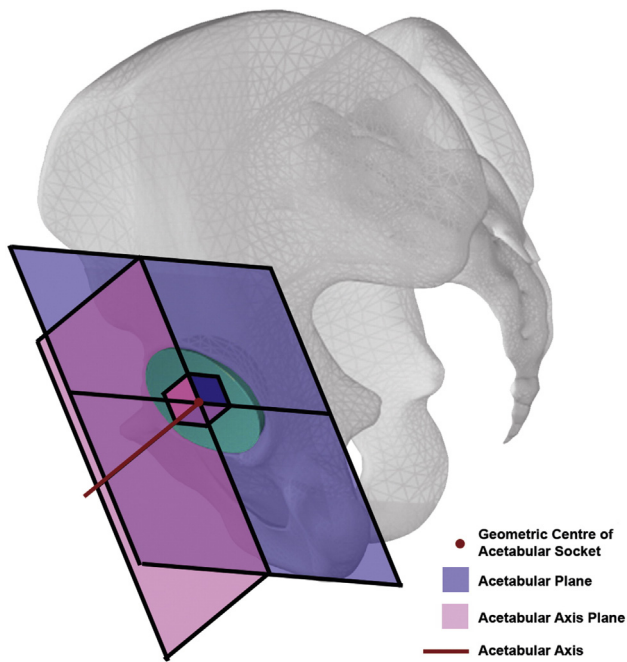


Fig. 1. Diagram defining the acetabular axis (AA) and the acetabular axis plane.

The aim of this research synthesis is to compare the planned orientation of the acetabular cup, as per the manufacturers' instructions, to the literature based recommended safety zones and surgical techniques to highlight any potential disparities between them and, more importantly, to identify a common consensus of best practice. Greater understanding of the optimal acetabular cup orientation would reduce the risk of revision surgery and alleviate the economic burden of revision surgery.

Reference System Definitions

Acetabular Axis

The acetabular axis originates at the geometric centre of the acetabular socket and is orthogonal to the acetabular plane (Fig. 1) [21]. The acetabular axis plane lies on the acetabular axis and is perpendicular to the acetabular plane.

The three different reference systems (operative, radiographic and anatomical), are used together with the acetabular axis to quantify acetabular orientation. These are outlined below. For brevity's sake, the reader is directed elsewhere [3,16] for a more complete description of these reference systems.

Operative Reference System

The operative reference system is defined [18] by the intra-operative pose of the patient on the operating table. The recommended inclination angle (δ) is defined when the arm of the guide is parallel to the operating table and the recommended operative anteversion angle (ϕ) is described when the arm of the guide is parallel to the longitudinal axis of the patient. Therefore, in the ideal lateral decubitus orientation, with the sagittal plane horizontal, and coronal and transverse planes both vertically oriented, δ is the angle between the acetabular axis and the sagittal plane whilst ϕ is the angle between acetabular axis as projected onto the sagittal plane and the coronal plane (Fig. 2).

Radiographic Reference System

The radiographic definition [3] of inclination and anteversion relies on measurements taken from x-rays which are used for preoperative planning and used postoperatively to measure the success of the procedure. This definition would also be used if the operation is carried out with the patient in the supine pose. The radiographic inclination angle (θ) is defined as the angle between the longitudinal axis of the body and projection of the acetabular axis in the coronal plane and the radiographic anteversion angle (α) is the angle between the acetabular axis and the coronal plane [16] (Fig. 2).

Anatomical Reference System

The anatomical reference [22] defines the anatomical inclination (β) as the angle between the acetabular axis and the longitudinal axis of the patient and the anatomical anteversion (γ) as the angle between the acetabular axis, as projected onto the transverse plane, and the transverse axis [16]. The three reference systems are depicted in Fig. 2.

Methodology

The recommended position of the acetabular cup was collated from the literature [3,17–19] and academic textbooks [23–25]. The National Joint Registry for England and Wales was used to identify the most commonly used implants, the surgical guidelines for which were subsequently selected for inclusion in the analysis [26–33]. All orientations were transformed to the operative reference frame (δ , ϕ) for comparison using the equations below [16]:

$$\sin(\delta) = \sin(\theta) \cos(\alpha) = \sin(\beta) \cos(\gamma)$$

$$\tan(\phi) = \tan(\alpha) / \cos(\theta) = \sin(\gamma) \tan(\beta)$$

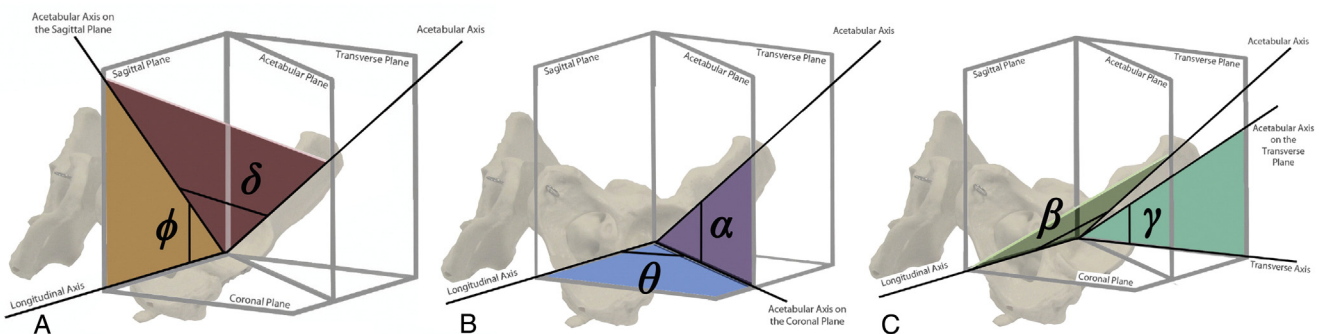


Fig. 2. Comparison of operative (A), radiographic (B) and anatomical (C) reference systems.

Table 1
Safety Guidelines for Inclination and Anteversion Angles from the Literature.

Source	Inclination					Anteversion				
	Original Definitions Degrees (°)	Original Reference Frame	Operative Degrees (°)	Radiographic Degrees (°)	Anatomical Degrees (°)	Original Definitions Degrees (°)	Original Reference Frame	Operative Degrees (°)	Radiographic Degrees (°)	Anatomical Degrees (°)
Lewinnick [4]	40 ± 10°	Radiographic	38 ± 11	40 ± 10	42 ± 12	15 ± 10°	Radiographic	21 ± 15	15 ± 10	25 ± 18
McCullum and Gray [18]	40 ± 10° Lateral Opening	Radiographic	36 ± 12	40 ± 10	45 ± 11	30 ± 10° Anteversion	Operative	30 ± 10	25 ± 11	36 ± 19
Harris [19]	30° Abduction	Radiographic	28	30	34	20° Forward Flexion	Operative	20	18	32
Pedersen [20]	<40° Tilt	Radiographic	35 ± 5	35 ± 5	36 ± 6	<10° Anteversion	Radiographic	6 ± 6	5 ± 5	10 ± 10

Table 2
Suggested Acetabular Cup Inclination and Anteversion Angles from Surgical Technique in Academic Textbooks.

Source	Inclination					Anteversion				
	Original Definitions Degrees (°)	Original Reference Frame	Operative Degrees (°)	Radiographic Degrees (°)	Anatomical Degrees (°)	Original Definitions Degrees (°)	Original Reference Frame	Operative Degrees (°)	Radiographic Degrees (°)	Anatomical Degrees (°)
Jayson Total Hip Replacement [23]	45° Open	Radiographic	45	46	45	10°	Operative	10	10	7
Calandruccio Campbell's Operative Orthopaedics [21]	35° - 45° Inclination	Radiographic	39 ± 6	40 ± 5	41 ± 6	10°-20° Anteversion	Operative	15 ± 5	12 ± 5	19 ± 9
Charnley [24]	45° Inclination	Anatomical	45	45	45	0°	Anatomical	0	0	0
Muller [25]	45° Facing Laterally	Radiographic	44	45	46	10°	Operative	13 ± 3	9 ± 2	13 ± 3

Results

Compilation of the different recommended orientations of the acetabular cup from the literature showed a variety of orientations using different terms, reference and measurement systems. Table 1 displays the different guidelines from the literature in the original definitions and converted operative, radiographic and anatomical inclination and anteversion definitions.

The suggested inclination angles ranged from 24° to 50° and the suggested anteversion angles ranged from 0° to 40° in the operative reference frame.

The recommended orientations of the acetabular cup from a range of surgical techniques found in academic textbooks also showed a variety of orientations which are displayed in Table 2. The majority of the orientations used the radiographic reference system to describe the inclination angle and the operative reference system to describe

the anteversion angle. The range was considerably smaller than the literature guidelines with suggested inclination angles between 33° and 45° and the suggested anteversion angles ranging from 0° to 20° in the operative reference frame.

Fig. 3 details the comparison of the recommended safety zones from the literature and textbooks in the operative reference frame. The majority of the recommended implant orientations are contained within Lewinnick's definition of the safe zone however Harris is on the edge of the safe zone, Calandruccio Campbell's Operative Orthopaedics and Pedersen are partially overlapping the safe zone and Charnley is not at all contained within the Lewinnick safe zone.

Suggested orientations, as per the manufacturers' instructions, showed less variability in the adopted reference system and recommended orientation. With the exception of DePuy, most manufacturers used the radiographic definition to describe the

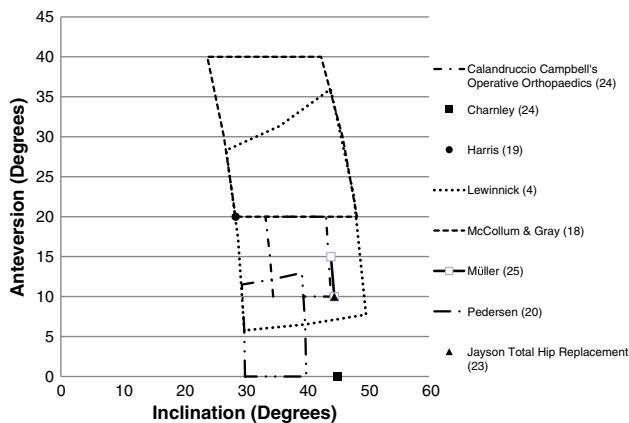


Fig. 3. Recommended safe zones of the acetabular cup in the operative reference system.

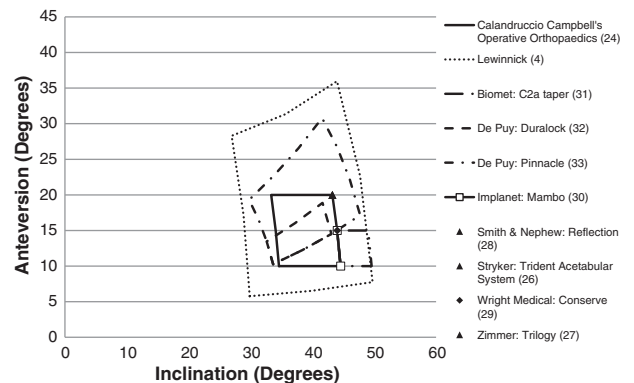


Fig. 4. Comparison of desired orientation of the acetabular cup from the safety guidelines from literature and current surgical guidelines: operative definition.

Table 3
Recommended Inclination and Anteversion Angles From Current Surgical Guidelines.

Source	Inclination					Anteversion				
	Original Definitions Degrees (°)	Original Reference Frame	Operative Degrees (°)	Radiographic Degrees (°)	Anatomical Degrees (°)	Original Definitions Degrees (°)	Original Reference Frame	Operative Degrees (°)	Radiographic Degrees (°)	Anatomical Degrees (°)
Biomet: C2a Taper [30]	47.25 ± 2.5 Inclination	Radiographic	47 ± 3	48 ± 3	48 ± 3	12.5 ± 2.5° Anteversion	Operative	13 ± 3	9 ± 2	12 ± 3
DePuy: Duralock [31]	40 ± 5 Abduction	Anatomical	38 ± 5	39 ± 5	40 ± 5	17.5 ± 2.5° Anteversion	Anatomical	15 ± 4	11 ± 3	18 ± 3
DePuy: Pinnacle [32]	42.5 ± 7.5 Abduction	Anatomical	39 ± 9	40 ± 9	43 ± 8	22.5 ± 7.5° Anteversion	Anatomical	21 ± 10	16 ± 7.0	23 ± 8
Implanet: Mambo [29]	45 Abduction	Radiographic	44	45	46	12.5 ± 2.5° Anteversion	Operative	13 ± 3	9 ± 2	12 ± 2.5
Smith and Nephew: Reflection [27]	45 Abduction	Radiographic	43	45	47	20° Anteversion	Operative	20	14	20
Stryker: Trident [25]	45 Abduction	Radiographic	43	45	47	20° Anteversion	Operative	20	14	20
Wright Medical: Conserve [28]	45 Vertical	Radiographic	44	45	46	15° Anteversion	Operative	15	11	15
Zimmer: Trilogy [26]	45 Abduction	Radiographic	43	45	47	20° Forward Flexion	Operative	20	14	20

inclination angle and the operative definition to describe the anteversion angle. Table 3 displays the range in the suggested orientation of the implants in the original definition and the operative, radiographic and anatomical inclination and anteversion definitions. Results show that the suggested operative inclination angle range is between 30° and 50° and operative anteversion angle range is between 10° and 31°. The range for both operative inclination and operative anteversion is smaller than the safety guidelines from the literature.

Fig. 4 details the manufacturers' recommended orientation of the acetabular cup in the operative reference system with respect to the Lewinnick and Campbell's Operative Orthopaedics recommended "safe zones". The majority suggest that the acetabular cup should be placed at an inclination angle of 45°. The recommended anteversion angle is more variable with most around 15–20°. A comparison of the suggested orientation of the acetabular cup from the safety guidelines from literature and current surgical guidelines highlighted that 88% of the surgical guidelines are fully contained within the recommended Lewinnick "safe zone". However, 75% are concentrated in the bottom right quadrant. 63% of the suggested implant positions are on the border of the Campbell's Operative Orthopaedics "safe zone."

Discussion

The orientation of the acetabular cup is one of the most important factors under the surgeon's control [14] and as a result it is crucial that the surgeon has accurate and precise control over the orientation of the implanted acetabular cup [34]. There is no standardised measurement method or agreed orientation and this has resulted in variability of methods, safe zones and cup orientations [7,10,20,35,36]. Convert-

ing all literature and manufacturers' suggested guidelines into the operative reference system has enabled direct comparisons to be made. As highlighted in the results, the definition used matters, there is no consensus on the definitions and little overlap occurs between any of the values given by different definitions. This further emphasises the wide variability in the literature for the suggested orientation of the acetabular cup.

The results demonstrate a limitation with the use of the three definitions and suggest the need for a fourth. Current mechanical guides require the surgeon to have precise control of two planes at once as the inclination and anteversion angles are measured separately as shown below in Fig. 5. This means intra-operatively the orientation suggested by the mechanical guide demonstrates the inclination angle on the coronal plane and the anteversion angle in the sagittal plane.

Using Murray's [16] definitions, mechanical guides show a radiographic inclination angle and an operative anteversion angle. Most of the manufacturer's safety guidelines and the surgical techniques from textbooks use this combination to define the suggested acetabular cup orientation. To overcome this discrepancy we suggest this combination should be referred to as the surgical reference system. As demonstrated in Fig. 6, inclination is the angle between the longitudinal axis of the patient and the acetabular axis as projected onto the coronal plane. Anteversion is the angle between the longitudinal axis of the patient and the acetabular axis as projected onto the sagittal plane.

Although most of the manufacturer's use this surgical reference system; and this is used during the operation, most of the literature is based on measurements taken postoperatively on radiographs. The implant is therefore positioned using the surgical definition but

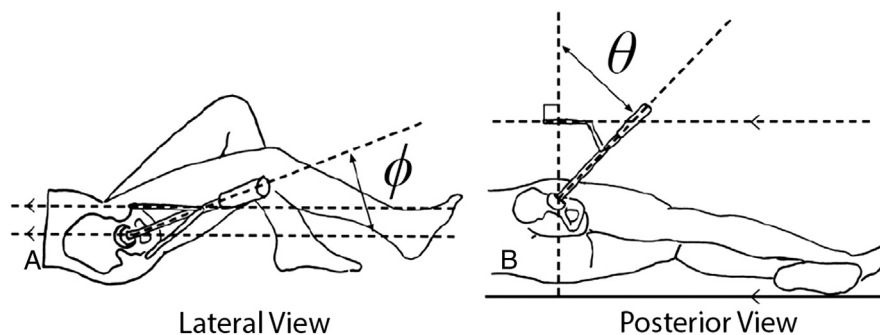


Fig. 5. Surgical definition of anteversion (A) and inclination (B) angles.

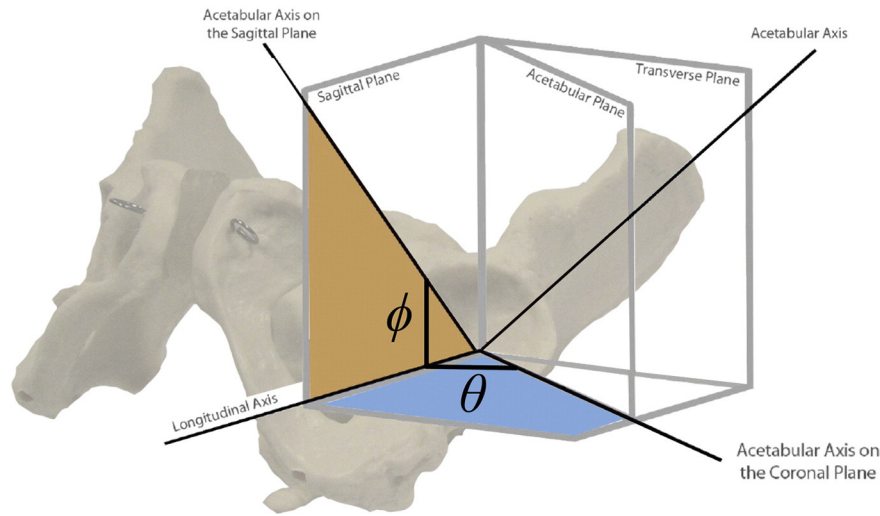


Fig. 6. Surgical reference system.

evaluated using a radiographic orientation. Using the surgical definition intra-operatively and a radiographic definition postoperatively can lead to further discrepancy and confusion.

When reviewing the recommended implant orientations in the surgical reference system, there is no suggested safe zone in the literature or the surgical techniques that corresponds with all the suggested implant orientations from the manufacturers. Although 87.5% of the surgical guidelines are contained within the Lewinnick safe zone, they are congregated at the bottom right corner and the majority of the surgical guidelines within the Campbell's Operative Orthopaedics recommended orientation are on the edge of that zone. This puts a surgeon in a quandary: small deviations from the manufacturers' recommended orientation may place the cup in an orientation out with a safe zone, but contrastingly, aiming for the middle of the safe zone will contradict manufacturers' guidelines. In the surgical reference system, the Lewinnick safe zone is no longer square which makes it difficult for the surgeon to ensure the implant is within the recommended area. Creating a square which is based on the Lewinnick zone and restricting anteversions to no less than 5° and no more than 30°, suggest a new safety zone centred on the bottom right hand corner of Lewinnick's zone at approximately 40° surgical inclination and 17–18° surgical anteversion. This cup placement may be a simple target which could be used for all such arthroplasties irrespective of implant manufacturer. As this safe zone is defined in the surgical definition, it could be used with current surgical guidelines and used intra-operatively removing the need for surgeons to convert between

definitions and the subsequent potential for error. The vast majority of the suggested acetabular cup positions from the safety guidelines are enclosed within this area (Fig. 7). Nevertheless, before such a safe zone can be recommended for surgical use, further validation of this safety zone would be required.

Comparison of the results displayed in Tables 1, 2 and 3 showed a larger range in the recommended anteversion angles compared to inclination angles. Anteversion is harder than inclination to evaluate using current techniques [37] which could account for this wide range; however, the anteversion angle is critical as it has been shown to be one of the biggest influencing factors that can lead to dislocation [4,5,38]. The significance of the anteversion angle along with the wide range of values found further emphasises the need for more clarity on orientation guidelines.

There are a number of limitations in these measurement systems which must be taken into consideration. Operatively, this reference system relies on the patient being positioned and remaining on table in a perfect lateral decubitus pose. Radiographically, as the image is a projection, any rotation of the pelvis can add error [39]. Pelvic tilt, which is the angle between anterior pelvic plane and the coronal plane [36] must be taken into consideration when positioning the acetabular cup. Knowing the exact orientation of the hip on the operating table is very difficult [17]; however, the orientation of the cup is critically dependent on the position of the patient's pelvis [35]. Pelvic tilt has been shown to have a direct impact on the anteversion angle [40,41], therefore this should be taken into consideration in any measurement system. Correct orientation of the acetabular cup is also dependent on other variables such as the orientation of the femoral stem, design of the implant and individual patient anatomy. Each of these factors must also be taken into consideration when positioning the acetabular cup.

This study demonstrates there is no consensus in the optimum orientation of the acetabular component in THA. Ensuring that all literature and guidelines are in the same definition would, at least, allow direct comparison to be made between the current approaches enabling further research to relate outcomes to cup orientation. This could lead to a reduction in the variability of recommended orientations and the development of clearer definitions and better standards.

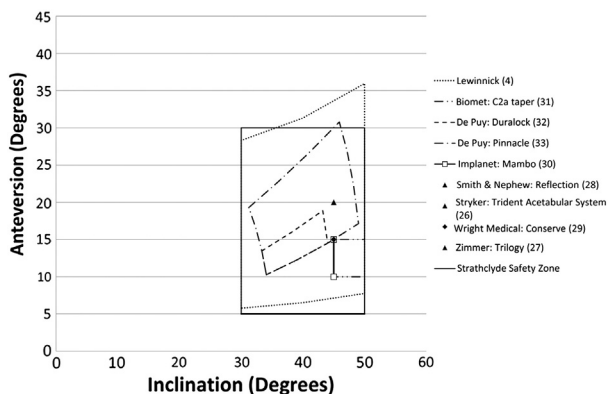


Fig. 7. Comparison of desired orientation of the acetabular cup from current surgical guidelines and the proposed Strathclyde Safety Zone: surgical definition.

Acknowledgments

The authors would like to thank the Engineering and Physical Sciences Research Council for providing the funding for this research.

References

- Najarian BC, Kilgore JE, Markel DC. Evaluation of component positioning in primary total hip arthroplasty using an imageless navigation device compared with traditional methods. *J Arthroplasty* 2009;24:1.
- Oki H, Ando M, Omori H, et al. Relation between vertical orientation and stability of acetabular component in the dysplastic hip simulated by nonlinear three-dimensional finite element method. *Artif Organs* 2004;28(11):1050.
- Lewinnek GE, Lewis JL, Tarr R, et al. Dislocations after total hip replacement arthroplasties. *J Bone Joint Surg Am* 1978;60-A(2):217.
- Masaoka T, Yamamoto K, Shishido T, Katori Y, Mizoue T, Shirasu H, Nunoda D. Study of hip joint dislocation after total hip arthroplasty. *Int Orthop (SICOT)* 2006;30:26.
- Nishii T, Sugano N, Miki H, et al. Influence of component positions on dislocation. *J Arthroplasty* 2004;19(2):162.
- Yuan LJ, Shih CH. Dislocation after total hip arthroplasty. *Arch Orthop Trauma Surg* 1999;119:263.
- D'Lima DD, Urquhart AG, Buehler KO, et al. The effect of the orientation of the acetabular and femoral components on the range of motion of the hip at different head-neck ratios. *J Bone Joint Surg* 2000;82-A(3):315.
- Kummer FJ, Shah S, Iyer S, et al. The effect of acetabular cup orientations on limiting hip rotation. *J Arthroplasty* 1999;14(4):509.
- Robinson RP, Simonian PT, Gradisar IM, et al. Joint motion and surface contact area related to component position in total hip arthroplasty. *J Bone Joint Surg Br* 1997;79-B(1):140.
- Malik A, Maheshwari A, Dorr LD. Impingement with total hip replacement. *J Bone Joint Surg Am* 2007;8:1932.
- National Joint Registry. National Joint Registry for England and Wales 8th Annual Report. National Joint Registry; 2011 ISSN 1745–1450.
- DeChenne CL, Jayaram U, Lovell T, et al. A novel acetabular alignment guide for THR using selective anatomic landmarks on the pelvis. *J Biomech* 2005;38:1902.
- Minoda Y, Ohzono K, Aihara M, et al. Are acetabular component alignment guides for total hip arthroplasty accurate? *J Arthroplasty* 2010;25(6):986.
- Echeverri S, Leyvraz P, Zambelli P, et al. Reliable acetabular cup orientation with a new gravity-assisted guidance system. *J Arthroplasty* 2006;21(3):413.
- Revell M, Davis ET. Hip replacement: clinical perspectives. In: Revell PA, editor. *Joint replacement technology*. Cambridge: Woodhead Publishing; 2008.
- Murray DM. The definition and measurement of acetabular orientation. *J Bone Joint Surg Br* 1993;75-B(2):228.
- McCollum DE, Gray WJ. Dislocation after total hip arthroplasty. Causes and prevention. *Clin Orthop Relat Res* 1990;261:159.
- Harris W. Advances in surgical technique for total hip replacement: without and with osteotomy of the greater trochanter. *Clin Orthop Relat Res* 1990;146:188.
- Pedersen DR, Callaghan JJ, Brown TD. Activity-dependence of the "safe zone" for impingement versus dislocation avoidance. *Med Eng Phys* 2005;27:323.
- Yoon Y, Hodgson AJ, Tonetti J, et al. Resolving inconsistencies in defining the target orientation for the acetabular cup angles in total hip arthroplasty. *Clin Biomech* 2008;23:253.
- Calandruccio RA. Arthroplasty of hip. In: Crenshaw AH, editor. *Campbell's Operative Orthopaedics*, Vol. 2. St. Louis: CV Mosby; 1987. p. 1213.
- Walker PS. *Human joints and their artificial replacements*; 1977.
- Jayson MIV. *Total hip replacement*. Sector Publishing Ltd; 1971 0950145815.
- Canale ST, Beaty JH. *Campbell's Operative Orthopaedics*. 11th ed. Philadelphia, Pennsylvania: Mosby Elsevier; 2008. 978-0-323-03329-3.
- SL, Turek. *Orthopaedics Principles and Their Application* 4th ed. Philadelphia: J.B. Lippincott Company, 1984. ISBN 0-397-50604-X.
- Stryker. *Trident Acetabular System: Hemispherical Surgical Protocol*; 2009.
- Zimmer. *Trilogy Acetabular System: Surgical Technique*; 2010.
- Smith & Nephew. *Reflection*; 2006.
- Wright Medical Technology. *Conserve Total Super-fix Acetabular System: Surgical Technique*; 2005.
- Implanet. *Mambo Hip Cemented Cup*.
- Biomem Orthopedics. *C2a- Taper Ceramic on Ceramin Articulation*; 2007.
- De Puy. *Duraloc Option Ceramic Acetabular Cup, System*; 2005.
- De Puy. *Pinnacle Acetabular, System*; 2006.
- Bosker BH, Verheyen CCPM, Horstmann WG, et al. Poor accuracy of freehand cup positioning during total hip arthroplasty. *Arch Orthop Trauma Surg* 2007;127:375.
- Haaker RGA, Tiedjen K, Ottersbach A, et al. Comparison of conventional versus computer-navigated acetabular component insertion. *J Arthroplasty* 2007;22(2):151.
- Wan Z, Malik A, Jaramaz B, et al. Imaging and navigation measurement of acetabular component position in THA. *Clin Orthop Relat Res* 2009;467:32.
- Ackland MK, Bourne W, Uhthoff HK. Anteversion of the acetabular cup: measurement of angle after total hip replacement. *J Bone Joint Surg Br* 1986;68-B(3):409.
- He R, Yan S, Wu L, et al. Position of the prosthesis and the incidence of dislocation following total hip replacement. *Chin Med J* 2007;120(13):1140.
- Widmer KH, Zurfluh B. Compliant positioning of total hip components for optimal range of motion. *J Orthop Res* 2004;22:815.
- Fabeck L, Farrock D, Tolley M, et al. A method to measure acetabular cup anteversion after total hip replacement. *Acta Orthop Belgica* 1999;65(4):487.
- Babisch JW, Layher F, Amiot LP. The rationale for tilt-adjusted acetabular cup navigation. *J Bone Joint Surg Am* 2008;90:357.